

# Three-Year Efficacy and Safety of a Silicone Oil-Filled Foldable-Capsular-Vitreous-Body in Three Cases of Severe Retinal Detachment

Xiaofeng Lin, Xuyuan Sun, Zhenfang Wang, Zhaoxin Jiang, Yaqin Liu, Peijuan Wang, and Qianying Gao

State Key Laboratory of Ophthalmology, Zhongshan Ophthalmic Center, Sun Yat-sen University, Guangzhou, China

**Correspondence:** Qianying Gao, State Key Laboratory of Ophthalmology, Zhongshan Ophthalmic Center, Sun Yat-sen University, 54 Xianlie South Road, Guangzhou, 510060, China; gaoqy@mail.sysu.edu.cn

**Received:** 25 May 2015

**Accepted:** 12 October 2015

**Published:** 1 February 2016

**Keywords:** vitreous substitute; retinal detachment; foldable capsular vitreous body; silicone oil

**Citation:** Lin X, Sun X, Wang Z, et al. Three-year efficacy and safety of a silicone oil-filled foldable-capsular-vitreous-body in three cases of severe retinal detachment. *Trans Vis Sci Tech.* 2016;5(1):2, doi:10.1167/tvst.5.1.2

**Purpose:** We previously designed a novel foldable capsular vitreous body (FCVB) to treat severe retinal detachment and evaluated its performance in a 1-year follow up study. The purpose of this study was to determine the efficacy and safety of a silicone oil (SO)-filled FCVB in a 3-year follow-up.

**Methods:** Standard three-port pars plana vitrectomy was performed, and the FCVB was triple folded and implanted in the vitreous cavity of three eyes. The SO then was injected into the capsule to support the retina. The eyes were examined using Goldmann applanation tonometry, fundus photography, optical coherence tomography (OCT), noncontact specular microscopy, and ultrasound biomicroscopy over a 3-year implantation period.

**Results:** At the 3-year follow-up, retinal reattachment was achieved in all three cases, with steady intraocular pressure. The visual acuity showed slight fluctuations, and it was slightly increased compared to baseline. Optical coherence tomography revealed decreased retinal thickness and an altered retinal structure in the implanted eyes compared to the control eyes. No keratopathy, glaucoma, SO leakage, SO emulsification, or other apparent complications occurred during the observation period.

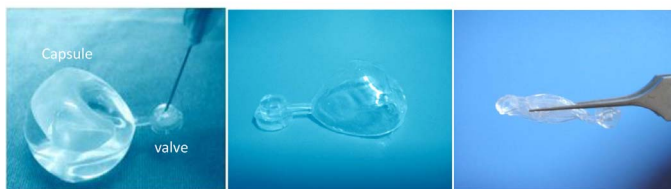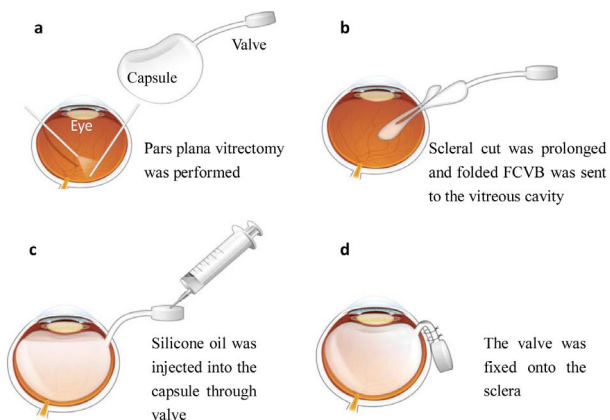
**Conclusion:** The SO-filled FCVB was effective and safe as a vitreous substitute in three eyes over a 3-year observation period.

**Translational Relevance:** Silicone oil emulsification is a severe complication after retinal detachment surgery. On the basis of animal experiments, we investigated a new strategy and product, the FCVB, to overcome this complication. In this pilot study, FCVB limited SO emulsification and migration. This study could lay the foundation for a further multicenter clinical trial.

## Introduction

The natural vitreous is a transparent gelatinoid structure, which occupies four-fifths of the volume of the eye. The physiological function of the vitreous body involves supporting adjacent posterior segment structures, serving as an ocular refractive medium and a cell barrier to inhibit cell migration from the retina to the vitreous cavity.<sup>1</sup> Pars plana vitrectomy, combined with artificial vitreous substitutes, is an important treatment for severe retinal detachment (RD) caused by various retinopathies, such as proliferative vitreoretinopathy, proliferative diabetic

retinopathy, and endophthalmitis.<sup>2-6</sup> A number of artificial vitreous substitutes (e.g., inert gas, silicone oil [SO], heavy SO, and hydrogels) have been adopted.<sup>7-14</sup> Among these, SO, introduced by Cibis in 1962,<sup>9</sup> has been the most important adjunct for internal tamponade in the treatment of complicated retinal or choroidal detachment for the past 5 decades. However, SO is not always successful, and an anatomical success rate of approximately 70% has been reported,<sup>8</sup> together with various complications, including cataracts, keratopathy, glaucoma,<sup>12</sup> emulsification,<sup>15</sup> and translocation of the SO. Despite half a century of efforts to find a substance to replace the

**Fig. 1A Preparation of FCVB implantation****Fig. 1B Procedure of FCVB implantation**

**Figure 1.** (A) Preparation of FCVB for implantation. The air tightness of the FCVB capsule was checked with a syringe needle through the valve. The capsule then was aspirated to a vacuum state, and adjusted to a special shape; then, the capsule was three-folded like a spindle. (B) Procedure for the FCVB implantation surgery. *a*, Pars plana vitrectomy was performed. *b*, A scleral cut was prolonged and folded FCVB was sent to the vitreous cavity. *c*, SO was injected into the capsule through the valve. *d*, The valve was fixed onto the sclera.

natural vitreous of the eye, an ideal and permanent vitreous body has yet to be found.<sup>7,8,16,17</sup>

Vitreous substitution is deemed one of the most interesting and challenging fields of research in ophthalmology.<sup>7</sup> Challenges with vitreous substitution include the need to make a mini-implantation incision. The refraction and transparency of the substitution also are crucial, as is the intraocular location of the substitute, which is in close contact with very delicate tissues, such as the retina, ciliary body, lens, and anterior chamber.

In our previous studies,<sup>18–21</sup> we proposed a new vitreous substitution strategy involving a novel foldable capsular vitreous body (FCVB) to avoid the aforementioned complications. We conducted a pilot study of FCVB injected with a balanced salt solution (BSS)<sup>22</sup> in 11 patients with severe RD over a 3-month period. Some BSS leakage occurred because of tiny

holes in the capsule of the FCVB. The leakage was confirmed in an *in vitro* study of the hydrolytic stability of the BSS-filled FCVB.<sup>23</sup> In contrast, no leakage occurred when SO was used in the capsule of FCVB, as shown in a hydrolytic stability test and demonstrated in three patients implanted with an SO-filled FCVB in a clinical trial.<sup>23</sup> In this clinical trial, the SO-filled FCVB showed good stability and efficacy. In the present study, we investigated the efficacy and safety of the SO-filled FCVB during a 3-year follow-up period.

## Methods

The inclusion criteria, exclusion criteria, treatment procedures, and follow-up evaluations have been described previously.<sup>23</sup> Only patients who had severe RD that could not be reattached easily with SO tamponade were included. If a patient had serious ocular inflammation, a single eye, dysfunction of any important organ, or any other condition that the researchers deemed unsuitable for this clinical trial, the patient was excluded. Each participant underwent standard three-port pars plana vitrectomy and FCVB implantation, and SO was injected into the capsule to fill the FCVB (Fig. 1). Follow-up examinations were performed (3 days, and 1, 2, and 4 weeks, and 2, 3, 6, 9, 12, 115, 18, 21, 24, 30, 33, and 36 months) and included visual acuity, Goldmann applanation tonometry, slit-lamp microscopy, direct ophthalmoscopy, fundus photography, optical coherence tomography (OCT), noncontact specular microscopy, and ultrasound biomicroscopy. Complete retinal reattachment after 3 years was deemed the primary outcome measurement, and the secondary outcome measurements included visual acuity and intraocular pressure (IOP).

The study was approved by the Sun Yat-sen University Medical Ethics Committee (Zhongshan Ophthalmic Center Medical Ethics [2009] No. 07). The clinical trial strictly adhered to the principles of the World Medical Association's Declaration of Helsinki and has been registered with ClinicalTrials.gov (Clinical Trials, Gov. ID: NCT00910702) and the Chinese Clinical Trial Register (ChiCTR-TNC-00000396).

## Results

### Baseline Information

Three subjects (three eyes) were enrolled in this study between December 2009 and January 2010.

Case 1 (22 years, female) had a cataract and severe ocular rupture, with retinal and choroidal detachment. Case 2 (53 years, male) had redetachment with subretinal SO after SO tamponade and no lens. Case 3 (19 years, male) had redetachment, with SO in the anterior chamber after SO and C<sub>3</sub>F<sub>8</sub> tamponade, scleral buckling, and an absent lens. Written informed consent was obtained from all subjects.

## Efficacy Evaluation

Retinal reattachment in the cases was examined by fundus photography and OCT. As shown in **Figures 2A to 2C**, the fundus was visible and clear in all three patients at the 1-, 2-, and 3-year follow ups. There were no obvious differences between the images at any of the follow ups, indicating that the FCVB-supported fundus was stable during the 3-year implantation period. The eye in Case 1 had severe ocular rupture and retinal and choroidal absence. Cases 2 and 3 had already failed to respond to SO tamponade. Optical coherence tomography showed the retina was reattached and there was smooth contact between the FCVB and retina, although the thickness was decreased and the structure was different compared to the retina of control eyes, which occurred at initial follow ups (at 4 weeks, and 6 and 12 months) in consequence of healing and scarring. Admittedly, this is a possibility of compression damage of FCVB to the retina, whereas the thickness and the structure showed no apparent change during 3-year follow-ups, which may need a long time to confirm.

As shown in **Figure 2D**, the visual acuity in Case 1 improved from no light perception (NLP) to perception of hand motion (HM), fluctuated between light perception (LP) and perception of HM during the 3-year follow-up period, and showed the best HM/20 cm at the 9-month follow up. Case 2 exhibited LP 3 years after implantation, but fluctuated between LP and finger counting (FC) during the observation period. Case 2 achieved the best visual acuity of FC/5 cm at the 1-month follow up. In Case 3, the perception of HM/BE (before eyes) changed from no LP at baseline to LP at 3 years, fluctuated between LP and the perception of HM, and showed the best visual acuity of HM/90 cm at 1 year + 3 months.

The IOPs were markedly elevated in Cases 1 and 3 immediately after the FCVB implantation, whereas the IOP remained steady in Case 2. At the end of the 3 years, there were no differences in the IOP between the treated and control eyes in Cases 1 and 2, whereas the IOP of the treated eye was 5 mm Hg lower than

that of the control eye in Case 3. Steady IOP curves (**Fig. 2E**) indicated that no SO leakage occurred with the FCVB and that it restored the IOP.

## Safety Evaluation

No significant ocular inflammation, such as keratic precipitates, hypopyon, or aqueous flare, was observed (**Figs. 3A–3C**). No adverse events (e.g., exposure of the FCVB valve) or serious complications (e.g., keratopathy, glaucoma, and atrophy bulbi) occurred within the follow-up period. There also were no signs of leakage and emulsification of SO in the FCVB capsule (**Figs. 2A–C, 3A–C**).

No significant decreases were observed in the density of the corneal endothelial cells from baseline to 3 years after the FCVB implantation: from not detectable to 1541.7/mm<sup>2</sup> for Case 1, 1805/mm<sup>2</sup> to 1346/mm<sup>2</sup> for Case 2, and 1496.8/mm<sup>2</sup> to 1740.7/mm<sup>2</sup> for Case 3, as shown in **Figure 3G**. The images obtained by ultrasound biomicroscopy (**Figs. 3D–F**) pointed to smooth contact of the FCVB with the ciliary bodies and no crushing of these bodies. Based on the above data, it seems that FCVB could safely support a seriously detached retina.

## Discussion

In this 3-year clinical trial, retinal reattachment was successful in all subjects, and no keratopathy, glaucoma, SO leakage, SO emulsification, or any other apparent complications occurred in the observation period. The results demonstrated that FCVB filled with SO is effective and safe in the treatment of severe RD during a 3-year study period.

According to OCT, there was smooth contact between the FCVB and retina. However, the retinal thickness and structure were different when compared to the control retinas. These changes may not be related to the FCVB implantation, based on the following: First, the thickness of the operated retina did not show an apparent difference at the 3-month and 3-year follow-up time points. Second, Case 1 had severe ocular rupture and an incomplete retina. Cases 2 and 3 had a history of SO treatment failure, and it is very difficult to regain a normal retinal structure with severe and long-standing RD.

In the study, all cases were judged to have failed treatment with SO. If they had been treated with traditional procedures, the final visual acuity outcome would have been blindness. In addition, it would have been difficult to produce a normal-looking appear-

Fig. 2A Case 1

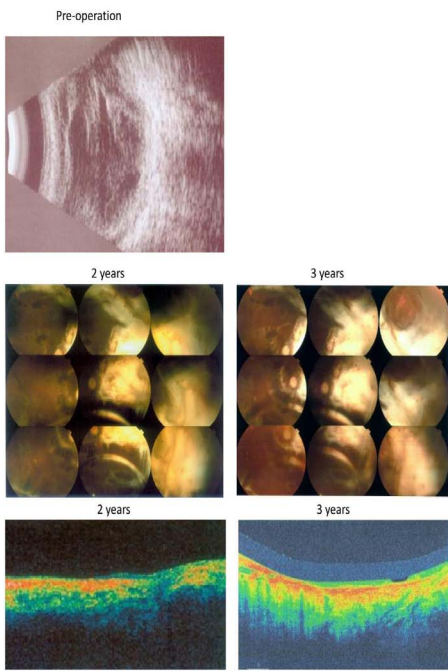


Fig. 2B Case 2

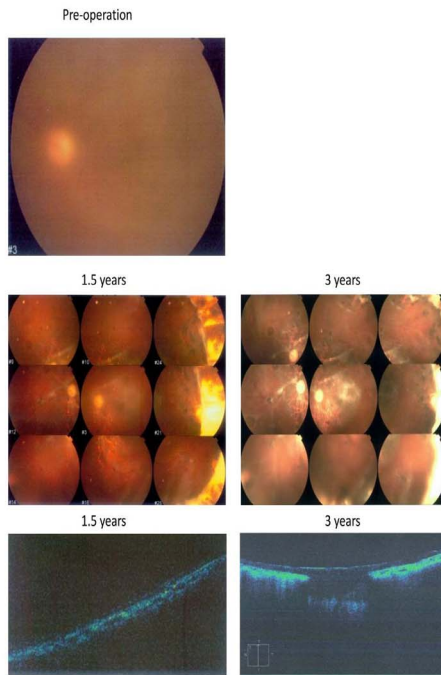


Fig. 2C Case 3

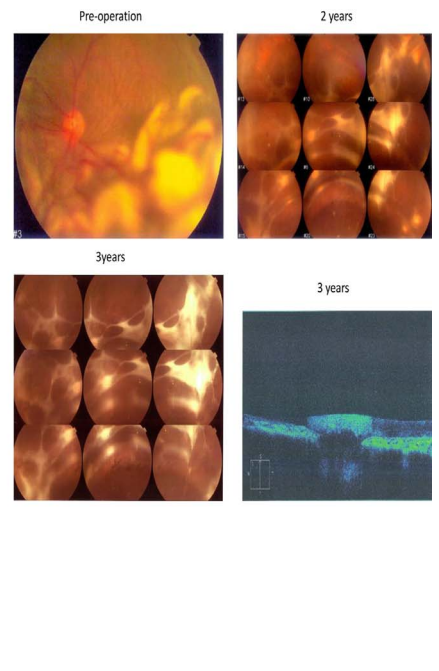


Fig. 2D

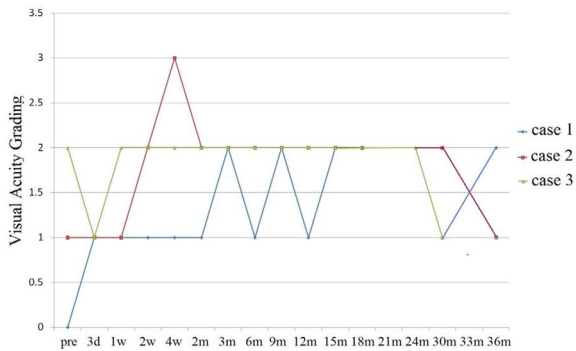
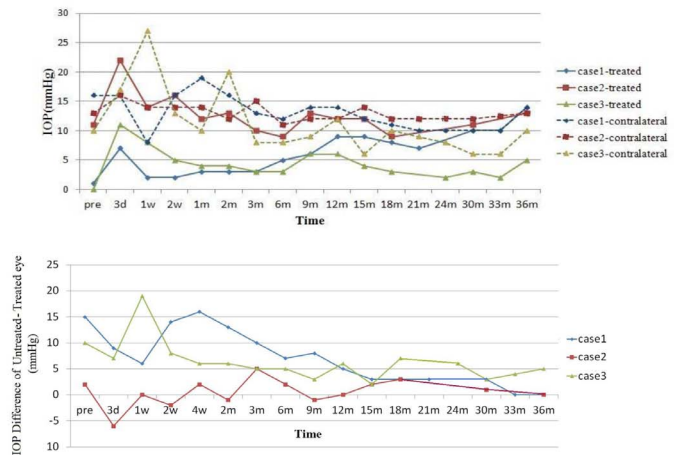


Fig. 2E



**Figure 2.** Efficacy of 3-year FCVB with SO implantation in three cases. (A–C) Fundus and OCT images of each patient. All three patients had severe RD at baseline. The fundus was visible and clear in all three cases, and there were no obvious differences between the images at the 2- and 3-year follow-ups, indicating that the FCVB-supported fundus was stable during the 3-year follow-up. OCT showed that the contact between the FCVB and retina was smooth, although the retinal thickness was decreased and the retinal structure was altered to some extent compared to the retina of the control eyes. The *arrow* indicates the 60- $\mu$ m thick capsular membrane. (D) Graded scores of visual acuity at each time point after the FCVB implantation. Visual acuity was graded according to the following system: NLP as 0, LP as 1, HM as 2, FC as 3,  $\geq 0.05$  as 4, and  $\geq 0.1$  as 5. The scores showed slight fluctuations, but the visual acuity of the three patients slightly increased compared to those at baseline. (E) IOP values and IOP differences between the untreated and treated eyes. The IOP was significantly elevated in Cases 1 and 3 immediately after the FCVB implantation, whereas it remained steady in Case 2. By the end of the 3-year follow-up, the IOPs of the treated and control eyes were not different in Cases 1 and 2, whereas the IOP in Case 3 was 5 mm Hg lower than that of the control eye. The differences between the untreated and treated eyes showed a tendency to decrease with time.

Fig. 3A Case 1

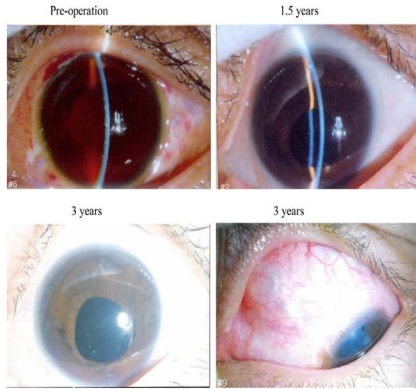


Fig.3B Case 2

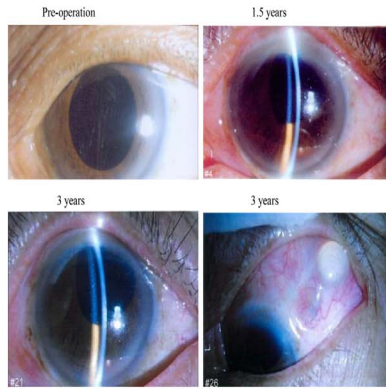


Fig.3C Case 3

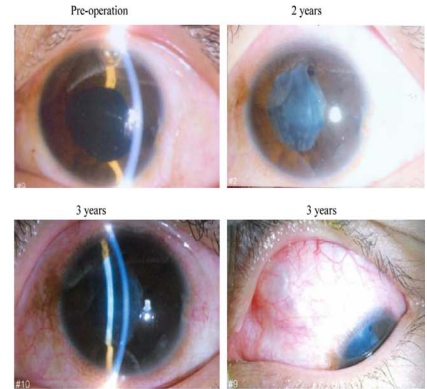


Fig.3D Case 1

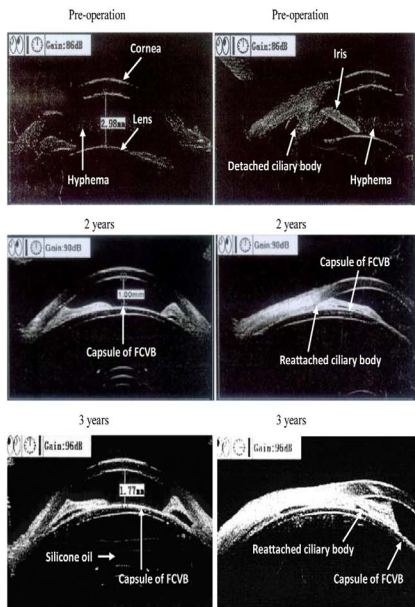


Fig.3E Case 2

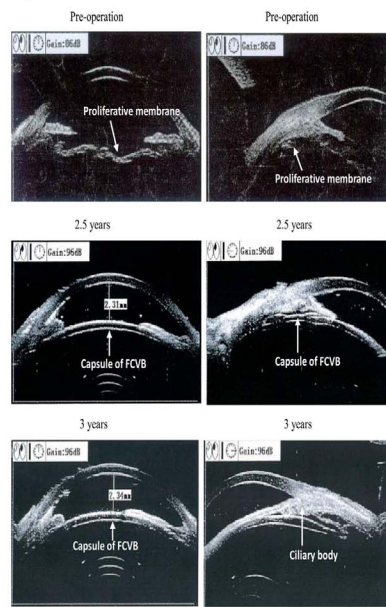


Fig.3F Case 3

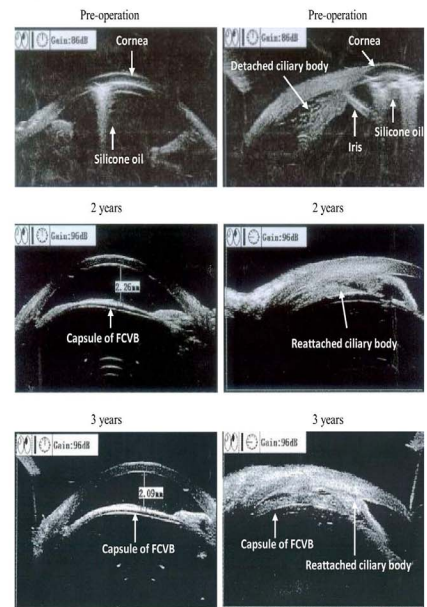


Fig.3G

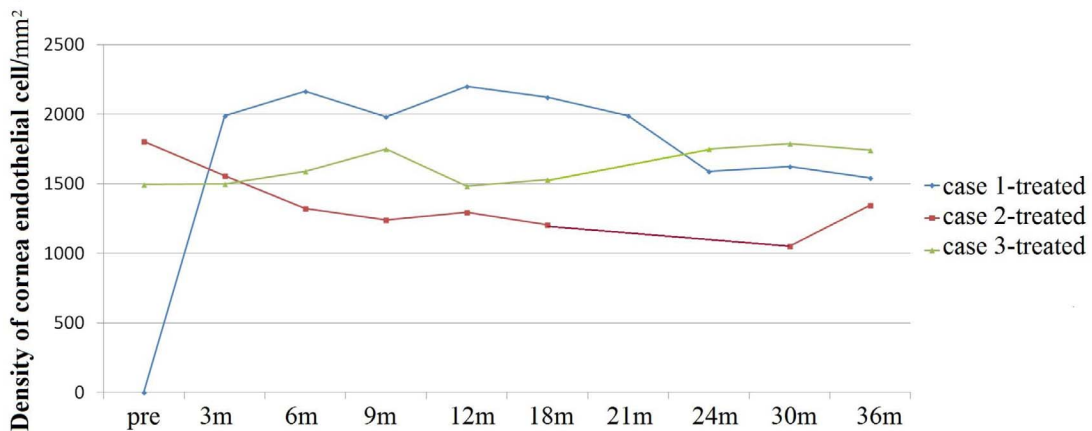


Figure 3. Safety of 3-year FCVB with SO implantation in the three cases. (A–C) Anterior segment imaging showed no observable inflammation. (D–F) Ultrasound biomicroscopy showed smooth contact of the FCVB with the ciliary bodies and no crushing of these bodies. (G) Number of corneal endothelial cells. There was no statistically significant difference in the density of the corneal endothelial cells between baseline and 3 years after FCVB implantation.

ance unless additional plastic surgery was performed. Given the initial severity of the RDs and retinal complications, an independent expert committee and the surgeon agreed on the need to retain the FCVB to avoid retinal redetachment and atrophy of the eyeball. If the FCVB were removed, the eyes would have a high risk of redetachment and further atrophy. As a result, an ophthalmectomy would be necessary.

Preservation of the visual acuity 3 years after FCVB implantation indicated the success of the new treatment. Moreover, the smooth contact between the retina and capsule of the FCVB shown in **Figures 2A to 2C** suggests that the FCVB was evenly distributed and that it supported the whole retina. Compared to the findings at the 1-year follow-up, the retina, ciliary bodies, and corneal structures were all stable, with no apparent changes, at the 3-year follow up. There was a tendency for fluctuations in visual acuity, but a longer observation time is needed to shed light on this issue.

Several factors contributed to the visual prognosis at 3 years. First, the included patients had severe ocular trauma and RD, with irreversible vision loss at baseline. In Case 1, the retina was absent, as shown by OCT. Second, as is well known, in the process of healing of ocular trauma and RD, the proliferation of exudative membrane and epiretinal membrane may occur, as was shown in Cases 2 and 3 by OCT. Third, an FCVB has not been implanted previously in eyes for three years. Compression damage to the retina caused by the long-term implanted FCVB may be a possible reason to explain the dismal visual prognosis of the cases in the present study.

During the observation period, the IOP of all the cases remained steady, and the esthetic appearance of the eyes was good, demonstrating that the FCVB did not affect the functioning of the ciliary body. Interestingly, although the IOP of Case 1 was markedly elevated after the FCVB surgery, the average IOP in the first year was 4.4 mm Hg compared to an average of 8 mm Hg in the second year and 11.3 mm Hg in the third year. This phenomenon indicated that the retina was reattached and that the function of the ciliary body might gradually recover after the FCVB treatment.

Emulsification is an important complication of intravitreal SO. Federman et al.<sup>15</sup> reported a 100% incidence of SO emulsification in 150 eyes in 1 year. Toklu et al.<sup>24</sup> reported that the SO emulsification time ranged from 5 to 24 months in 32 cases and that most emulsification occurred within 1 year. It

is notable that no emulsification was observed in any of the three cases within the 3 years in the present study. The absence of emulsification is likely mainly due to the barrier provided by the FCVB capsule. As reported previously, the FCVB prevents migration of proemulsifying substances, such as blood components,<sup>25</sup> and decreases the influence of the internal environment on the SO. This delays or stops the emulsification of SO and ensures the long-term viability of the SO-filled FCVB.

Previous studies reported that an FCVB capsule with a 300-nm aperture in the capsule served as a drug delivery system for dexamethasone sodium phosphate,<sup>20</sup> levofloxacin,<sup>26,27</sup> 5-fluorouracil,<sup>28</sup> voriconazole, and other potential drugs. In vivo and in vitro studies<sup>29</sup> reported that an FCVB sustainably and mechanically released 625 µg/mL of levofloxacin and effectively inhibited endophthalmitis in rabbits.

Our three cases still are under observation, and additional data will be reported periodically. Due to the good retinal support provided by the FCVB, a study of the FCVB combined with a retinal prosthesis currently is in process. Results of FCVB combined with polyethylene glycol<sup>30</sup> and polyvinylalcohol hydrogel<sup>31</sup> have been reported. Based on this trial, a nine-center clinical trial (122 cases) is enrolling patients in China to further evaluate the efficacy and safety of the FCVB in human eyes.

In conclusion, the FCVB filled with SO showed good efficacy and safety in the treatment of severe RD during a 3-year observation period. **The findings on this SO-filled FCVB, which mimics the natural vitreous, point to a novel research and therapy strategy.**

## Acknowledgments

The authors thank the patients and their families for their support of the study and all the attending staff at Zhongshan Ophthalmic Center for their help.

Partly supported by the National Key Technology Research and Development Program of the Ministry of Science and Technology of China (2012BAI08B02).

Disclosure: **X. Lin**, None; **X. Sun**, None; **Z. Wang**, None; **Z. Jiang**, None; **Y. Liu**, None; **P. Wang**, None; **Q. Gao** (C,P)

## References

1. Le GM, Bishop PN. Adult vitreous structure and postnatal changes. *Eye (Lond)*. 2008;22:1214–1222.
2. Quiram PA, Gonzales CR, Hu W, et al. Outcomes of vitrectomy with inferior retinectomy in patients with recurrent rhegmatogenous retinal detachments and proliferative vitreoretinopathy. *Ophthalmology*. 2006;113:2041–2047.
3. Pastor JC. Proliferative vitreoretinopathy: an overview. *Surv Ophthalmol*. 1998;43:3–18.
4. Karel I, Kalvodova B. Long-term results of pars plana vitrectomy and silicone oil for complications of diabetic retinopathy. *Eur J Ophthalmol*. 1994;4:52–58.
5. Castellarin A, Grigorian R, Bhagat N, Del PL, Zarbin MA. Vitrectomy with silicone oil infusion in severe diabetic retinopathy. *Br J Ophthalmol*. 2003;87:318–321.
6. Yoon YH, Lee SU, Sohn JH, Lee SE. Result of early vitrectomy for endogenous Klebsiella pneumoniae endophthalmitis. *Retina*. 2003;23:366–370.
7. Baino F. Towards an ideal biomaterial for vitreous replacement: historical overview and future trends. *Acta Biomater*. 2011;7:921–935.
8. Soman N, Banerjee R. Artificial vitreous replacements. *Biomed Mater Eng*. 2003;13:59–74.
9. Cibis PA, Becker B, Okun E, Canaan S. The use of liquid silicone in retinal detachment surgery. *Arch Ophthalmol*. 1962;68:590–599.
10. Vitrectomy with silicone oil or sulfur hexafluoride gas in eyes with severe proliferative vitreoretinopathy: results of a randomized clinical trial. Silicone Study Report 1. *Arch Ophthalmol*, 1992; 110:770–779.
11. Azen SP, Scott IU Jr, Flynn HW, et al. Silicone oil in the repair of complex retinal detachments. A prospective observational multicenter study. *Ophthalmology*. 1998;105:1587–1597.
12. Ichhpujani P, Jindal A, Jay KL. Silicone oil induced glaucoma: a review. *Graefes Arch Clin Exp Ophthalmol*. 2009;247:1585–1593.
13. Scott IU Jr, Flynn HW, Murray TG, et al. Outcomes of complex retinal detachment repair using 1000- vs 5000-centistoke silicone oil. *Arch Ophthalmol*. 2005;123:473–478.
14. Bhisitkul RB, Gonzalez VH. “Heavy oil” for intraocular tamponade in retinal detachment surgery. *Br J Ophthalmol*. 2005;89:649–650.
15. Federman JL, Schubert HD. Complications associated with the use of silicone oil in 150 eyes after retina-vitreous surgery. *Ophthalmology*. 1988;95:870–876.
16. la Cour M, Lux A, Heegaard S. [Visual loss under silicone oil]. *Klin Monbl Augenheilkd*. 2010;227:181–184.
17. Steijns D, Stilma JS. [Vitrectomy: in search of the ideal vitreous replacement]. *Ned Tijdschr Geneeskd*. 2009;153:A433.
18. Gao Q, Mou S, Ge J, et al. A new strategy to replace the natural vitreous by a novel capsular artificial vitreous body with pressure-control valve. *Eye (Lond)*. 2008;22:461–468.
19. Gao Q, Chen X, Ge J, et al. Refractive shifts in four selected artificial vitreous substitutes based on Gullstrand-Emsley and Liou-Brennan schematic eyes. *Invest Ophthalmol Vis Sci*. 2009; 50: 3529–3534.
20. Liu Y, Ke Q, Chen J, et al. Sustained mechanical release of dexamethasone sodium phosphate from a foldable capsular vitreous body. *Invest Ophthalmol Vis Sci*. 2010;51:1636–1642.
21. Liu Y, Jiang Z, Gao Q, et al. Technical standards of a foldable capsular vitreous body in terms of mechanical, optical, and biocompatible properties. *Artif Organs*. 2010;34:836–845.
22. Lin X, Ge J, Gao Q, et al. Evaluation of the flexibility, efficacy, and safety of a foldable capsular vitreous body in the treatment of severe retinal detachment. *Invest Ophthalmol Vis Sci*. 2011;52:374–381.
23. Lin X, Wang Z, Jiang Z, et al. Preliminary efficacy and safety of a silicone oil-filled foldable capsular vitreous body in the treatment of severe retinal detachment. *Retina*. 2012;32:729–741.
24. Toklu Y, Cakmak HB, Ergun SB, Yorgun MA, Simsek S. Time course of silicone oil emulsification. *Retina*. 2012;32:2039–2044.
25. Bartov E, Pennarola F, Savion N, Naveh N, Treister G. A quantitative in vitro model for silicone oil emulsification. Role of blood constituents. *Retina*. 1992;12:S23–S27.
26. Jiang Z, Wang P, Pan B, et al. Evaluation of levofloxacin release characteristics from a human foldable capsular vitreous body in vitro. *J Ocul Pharmacol Ther*. 2012;28:33–40.
27. Jiang Z, Wang T, Pan B, et al. Evaluation of the levofloxacin release characters from a rabbit foldable capsular vitreous body. *Int J Nanomedicine*. 2012;7:1–10.
28. Zheng H, Wang Z, Wang P, et al. Evaluation of 5-fluorouracil released from a foldable capsular vitreous body in vitro and in vivo. *Graefes Arch Clin Exp Ophthalmol*. 2012;250:751–759.

29. Wang T, Huang X, Gao Q, et al. A preliminary study to treat severe endophthalmitis via a foldable capsular vitreous body with sustained levofloxacin release in rabbits. *Invest Ophthalmol Vis Sci.* 2013;54:804–812.
30. Chen H, Feng S, Liu Y, et al. Functional evaluation of a novel vitreous substitute using polyethylene glycol sols injected into a foldable capsular vitreous body. *J Biomed Mater Res A.* 2013;101:2538–2547.
31. Feng S, Chen H, Liu Y, et al. A novel vitreous substitute of using a foldable capsular vitreous body injected with polyvinylalcohol hydrogel. *Sci Rep.* 2013;3:1838.